

## RESEARCH COMMUNICATION

# Spectrum of Cytological Findings in Patients with Neck Lymphadenopathy - Experience in a Tertiary Care Hospital in Pakistan

Saira Fatima\*, Sidra Arshad, Zubair Ahmed, Sheema H Hasan

### Abstract

**Introduction:** Lymph adenopathy is of great clinical significance as underlying diseases may range from a treatable infectious etiology to malignant neoplasms. In fact it is also essential to establish that the swelling in question is a lymph node. Fine needle aspiration cytology (FNAC) plays a vital role in solving these issues, nowadays being recognized as a rapid diagnostic technique because of its simplicity, cost effectiveness, early availability of results, accuracy and minimal invasion. FNAC is particularly helpful in the work-up of cervical masses and nodules because biopsy of cervical adenopathy should be avoided unless all other diagnostic modalities have failed to establish a diagnosis. **Objective:** To determine the epidemiological and cytomorphological patterns of enlarged neck nodes. **Study Design:** This retrospective observational study was performed at the Section of Histopathology, Aga Khan University Hospital (AKUH), Karachi, Pakistan. **Materials and Methods:** Three Hundred and seventy seven (377) neck swelling specimens obtained over a period of two and a half years registered from different regions of Pakistan were selected. Data were analyzed using SPSS 17. **Results:** Of a total of 377 cases of FNAC performed on neck nodes, the most frequent cause of lymphadenopathy was found to be tuberculosis with 199 cases (52.7%), followed by reactive lymphoid hyperplasia with 61 cases (16.1%). Metastatic carcinoma was found to be the third most common cause with 33 cases (8.7%). A diagnosis of lymphoproliferative disorder was rendered in 21 cases (5.5%). Acute and chronic non-specific inflammation was seen in 16 cases (4.2%). In 47 cases (12%) FNAC was inconclusive. **Conclusion:** In our study, the predominant cause of enlarged neck nodes was tuberculous lymphadenitis, followed by reactive lymphadenitis and malignant neoplasm, especially metastatic carcinoma and lymphoma. FNAC was helpful in establishing the diagnosis in approximately 98% of the cases.

**Keywords:** Cytology - FNAC - neck lymphadenopathy - tuberculosis - malignant neoplasms

*Asian Pacific J Cancer Prev*, 12, 1873-1875

### Introduction

Swelling in the neck could be due to disease involving salivary glands, lymph nodes, thyroid or skin. Lymphadenopathy is one of the most common problems encountered in neck. The cause may range from an infectious process to a malignant disease. Diagnosing the cause of these enlarged lymph nodes has always been a challenge for the physicians. Fine needle aspiration cytology (FNAC) helps solving the cause of enlarged lymph nodes. It is a tool to obtain material from a swelling for cytological examination, performed as an outpatient procedure. Superficial swellings are approached directly however deep swellings require ultrasound guidance. It has potential benefits over the other diagnostic modalities that have increased the utility of FNAC in recent past. It is simple, cost effective procedure that is minimally invasive with almost no complications. Results obtained by FNA are quick as compared to histopathological diagnosis. FNA

of superficial lesions need no anesthesia eliminating the risk of complications associated with anesthesia. No scar is formed at the site of FNA; other diagnostic modalities like incision biopsy or excision biopsy leave a scar. In case of suspected malignancy, FNAC is the best choice as it does not cause spread of tumor through the skin tract (Russel et al 2004). FNAC can also be of therapeutic use in a cystic swelling. Common causes of neck lymphadenopathy are inflammation, reactive hyperplasia, lymphoproliferative disorder and metastatic disease. The sensitivity of FNAC for the diagnosis of lymphadenopathy averages 90% with a specificity of 95% (Ahmed et al). The high degree of accuracy, low costs and minimally disruptive nature of the procedure makes FNAC a highly desirable alternative to open biopsy for investigation of cervical lymphadenopathy.

In our study we have analyzed fine needle Aspiration cytology of neck lymph nodes and studied the epidemiological and cytomorphological patterns of

Department of Pathology and Microbiology, Aga Khan University Hospital, Karachi, Pakistan \*For correspondence: saira.fatima@aku.edu.com

## Materials and Methods

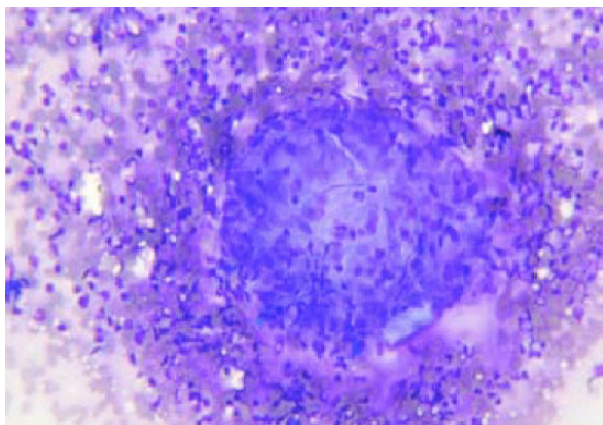
A retrospective study was conducted in the section of Histopathology, Department of Pathology and Microbiology, Aga Khan University Hospital Karachi during a period of two and a half years (January 2008 till June 2010).

Three hundred and seventy seven (377) neck swellings specimen obtained during the period of study, registered from different regions of Pakistan were selected. All swellings coded as “neck swelling” were retrieved; however swellings other than lymph nodes were excluded from the study. Epidemiological features such as age and gender were studied. Cytological diagnosis was recorded (see Figures 1 and 2). Data was analyzed using SPSS 17.

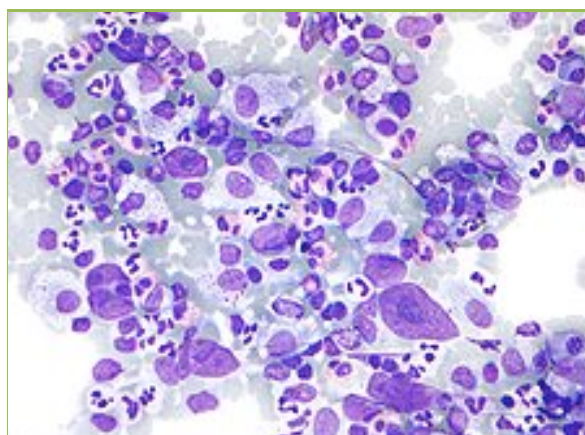
## Results

A total of 377 cases were included in the study after excluding swellings other than lymph nodes. There were 229 females (60.7%) and 148 (39.2%) males. The mean age was 32.7. Tuberculous lymphadenitis was the most common cytological diagnosis (Table 1).

The results were stratified into decades. In the first ten years predominant cause of lymphadenopathy was reactive in nature accounting for 43.5% of the



**Figure 1. Chronic Granulomatous Inflammation, Featuring Epithelioid Histiocytes with Giant Cells. Diff quick x10**



**Figure 2. Atypical Large Cells with Prominent Nucleoli in a Hodgkin's Lymphoma. Pap stain x20**

**Table 1. Overall Pattern of Cytological Findings**

Diagnosis	Number	(%)
Tuberculosis	199	(52.7)
Reactive lymphadenitis	61	(16.1)
Metastatic carcinoma	33	(8.70)
Lymphoproliferative disorder	21	(5.50)
Acute & chronic lymphadenitis	16	(4.20)
Non diagnostic	47	(12.0)
Total	377	(100)

cases in this group. The next common cause was tuberculous lymphadenopathy (21.7%). Although overall inconclusive, atypical cells were seen in 21.7% of the cases. These cases had fewer diagnostic cells and might have underlying lymphoproliferative disorder or a viral infection. A single patient was diagnosed as having lymphoproliferative disorder. The second decade is the age group when tuberculosis starts predominating than the other causes, approximately 62.2% the total cases in this group. Reactive lymph nodes being the second common cause (22.2%). In patients after 10 years up to the age of 50 year tuberculosis is over passing all other causes. After 50 years metastatic lymph nodes overshadowed the tuberculous reactive lymphadenopathy which became a smaller group and was no longer seen in age groups after 60 years. The metastatic tumors were mostly squamous cell carcinoma (SCC).

## Discussion

Other studies from Pakistan also reported tuberculous lymphadenitis as the most common pathology. One study (Ahmed et al., 2008) reported 36% tuberculosis in their study, others as 13% and 66.9 % (Kamal et al 1996., Shahid et al., 2010). A study from Saudi Arabia (El-Haq et al., 2003) had reactive lymphadenitis as the most common cause followed by tuberculosis (21%). An Indian study (Gupta et al., 2003) showed 59% of granulomatous lymphadenopathy. A different study (Lawrence et al., 2003) showed 47% of granulomatous lymphadenitis followed by 59% of reactive lymph nodes. Tuberculosis is seen as the most common cause of granulomatous inflammation seen in South East Asia and in developing countries. Initial western studies (Schelkum et al., 1991; Cheng et al., 1992) did not report tuberculosis in their studies. But after the world wide increasing incidence of HIV infection, tuberculosis is being reported from western population as a significant cause of cervical lymphadenopathy. In our study, tuberculosis was more common in females (75%) as compared to the males (25%). This may be because of poor nutrition and overall health in developing countries.

In a study (Agarwal et al., 2010) the commonest cause of lymph adenopathy in pediatric age group was reactive hyperplasia (70.9%) while tuberculous lymphadenitis was the predominant cause in adolescents and middle aged patients (40.8%). In our study similar findings were observed when stratified into age groups. Metastatic carcinoma was the major cause of lymphadenopathy in patients above 45 years of age (54.3%).

In our study lymphoproliferative disorder was reported in 5.3% of the cases. Further characterization was attempted whenever enough material was available in cell blocks. A panel of immunohistochemical stains including CD20, CD3, CD15, CD30, BCL-2, Tdt, CD10 & Ki-67 was used in the cases suspicious for lymphoproliferative disorder. Metastatic lymph nodes overall accounted for 8.46% of the cases. Predominant tumor was squamous cell carcinoma.

The FNAC has proved itself as an accurate, sensitive, specific and cost effective procedure in evaluation of palpable lumps, especially in lymph nodes. Overall sensitivity for lymphadenopathy in various studies had averaged above 90%, similarly specificity being above 95%. In our study FNAC was able to establish the diagnosis in approximately 98% of the cases. In 12% of the cases FNAC was inconclusive, diagnosis being as atypical cells or insufficient material. The variable factors responsible for these cases were performer experience, smear spreading technique and crushing artifacts.

Based on the finding in our study we found that FNAC is an extremely useful tool in the evaluation of palpable cervical lymph node, in majority of the cases excluding the need of a more invasive procedure and helping to initiate the appropriate treatment. The ancillary techniques such as immunohistochemistry may be employed whenever sufficient material is available for cell blocks and this would help in establishing the diagnosis.

In conclusion, FNAC is a reliable diagnostic tool in evaluation of lymphadenopathy for both screening and follow-up and can be performed as out patient's procedure. In our study, the predominant cause of enlarged neck nodes was tuberculous lymphadenitis, followed by reactive lymphadenitis and malignant neoplasm especially metastatic carcinoma and lymphoma. The FNAC was helpful in establishing the diagnosis in approximately 98% of the cases.

## Acknowledgements

The authors declare that there is no conflict of interest with this work.

## References

- Agarwal D, Bansal P, Ram, et al (2010). Evaluation of etiology of lymphadenopathy in different age groups using fine needle aspiration cytology; a retrospective study. *Internet J Pathol*, **10**, 2.
- Ahmed T, Naeem M, Ahmad S, Samad A, Nasir A (2008). Fine needle aspiration cytology and neck swellings in the surgical outpatient. *J Ayub Med Coll*, **2013**, 30-2.
- Cheng AT, Dorman B (1992). Fine needle aspiration cytology: the Auckland experience. *Aust NZ J Surg*, **62**, 368-72.
- El Haq IA, Chiedozi LC, Al Reyees FA, Kollur SM (2003). Fine needle aspiration cytology of head and neck masses. Seven years' experience in a secondary care hospital. *Acta Cytol*, **47**, 387-92.
- Gupta RK, Naran S, Lallu S, Fauk R (2003). The diagnostic value of fine needle aspiration cytology (FNAC) in the assessment of palpable supraclavicular lymph nodes; a study of 218 cases. *Cytopathology*, **8**, 511-4.
- Kamal F, Niazi S, Nag AH, Jaradi MA, Naveed IA (1996). Fine needle aspiration cytology (FNAC): an experience at King Edward Medical College, Lahore. *Pak J Pathol*, **7**, 33-6.
- Lawrence C, Imad AH, Shara NMNM (2003). Study of fine needle aspiration of head and neck masses. *Acta Cytol*, **47**, 387-92.
- Russel RCG, William NS, Bulstrode CJK (2004). Bailey and Love's short practice of surgery. 24th ed. London: Arnold.
- Schelkum PM, Grundy WG (1991). Fine needle aspiration biopsy of head and neck lesions. *J Oral Maxillofac Surg*, **49**, 262-7.
- Shahid F, MirzaT, Mustafa S, Sabahat S, Sharafat S (2010). An experiential status of fine needle aspiration cytology of head and neck lesions in a tertiary care scenario. *J Basic Applied Sci*, **6**, 159-62.
- Fernandes H, D Souza CRS, Thejawasni BN (2009). The role of fine needle aspiration cytology in palpable head and neck masses. *J Clin Diag Res*, **3**, 1719-25.
- Maharjan M, Hirachan S, Kafle PK et al, (2009). Incidence of tuberculosis in enlarged neck nodes, our experience. *Khatmandu Univ Med J*, **7**, 54-8.
- Tilak V, Dhaded AV, Rain R (2002). Fine needle aspiration cytology of head and neck masses. *Indian J Pathol Micobiol*, **45**, 23-30.