

## RESEARCH COMMUNICATION

# The Nodal Standard Uptake Value (SUV) as a Prognostic Factor in Head and Neck Squamous Cell Cancer

Umut Demirci<sup>1\*</sup>, Ugur Coskun<sup>2</sup>, U Ozgur Akdemir<sup>3</sup>, Mustafa Benekli<sup>2</sup>, Ozlem Kapucu<sup>3</sup>, Secil Ozkan<sup>4</sup>, Tansel Cakir<sup>3</sup>, Meltem Baykara<sup>2</sup>, Suleyman Buyukberber<sup>2</sup>

### Abstract

**Background/Aims:** The aim of present study is to evaluate the predictive and prognostic role of high [18F] fluoro-D-glucose (FDG) uptake of primary tumor and nodal metastasis in squamous cell carcinoma of head and neck (HNSCC). **Methodology and Patients:** Between February 2006 and July 2010, we retrospectively evaluated 64 patients with primary HNSCC in an institutional imaging trial. All patients who underwent evaluation pretreatment FDG-positron emission tomography/ computerized tomography (FDG-PET/CT) imaging and 33 (51%) had pre- and after treatment FDG-PET/CT imaging. All treatments were performed with curative intent. Abnormal FDG uptakes were analyzed using maximum standardized uptake values (SUVm). The disease-free survival (DFS) and overall survival (OS) were evaluated with several prognostic factors such as pre-treatment SUVm and % change in SUVm. **Results:** Tumor sites are nasopharynx (n= 29, 45.3%), larynx (n= 16, 25%), oropharynx (n= 13, 20.4%) and hypopharynx (n= 6, 9.4%). Median age was 58 (range: 16-87) and most patients (84.4%) had stage III/IV lesions. Objective response rate was 78.2%. The median primary tumor SUVm was 13.4 (range, 4.8–33.1), median nodal SUVm was 4.45 (range, 0–25.6) and median % change in SUVm was 74.1 (range, -61-100). On multivariate analysis, nodal SUVm and surgery remained significant predictors of DFS. There was no statistical significance found between survival and other factors. **Conclusions:** We have found that while nodal SUVm is prognostic for DFS, primary tumor SUVm and % change in SUVm are not.

**Keywords:** Head and neck SCC - [18F]fluoro-D-glucose POT/ CT - standardized uptake value

*Asian Pacific J Cancer Prev*, 12, 1817-1820

### Introduction

Head and neck cancer is the eighth most common cause of cancer death (Jemal et al., 2010). Over 60% of HNSCC patients present with locally advanced disease and have a 25% of forming distant metastases. Multimodal treatment with surgery, radiotherapy (RT), chemotherapeutic and targeted agents with multidisciplinary approaches has been used in patients with HNSCC (Pignon et al., 2009). The current approach of HNSCC patients have been induction chemotherapy and/or concurrent chemoradiotherapy (CCRT), thus it is ensuring to preserve organ and organ function. After definitive therapy, patients with locally advanced HNSCC may recur at the locoregional or distant relapse. The most important prognostic factor identified is the stage of the disease. However, we are needed in the additional prognostic factors that can predict treatment outcome. The therapy must be carefully individualized that are improved tumor control and survival (Monerrat et al., 2002; Forastierre et al., 2003; Urba et al., 2006; Pignon et al., 2009).

2-deoxy-2[18F] fluoro-D-glucose- positron emission tomography/ computerized tomography (FDG-PET/CT) is a physiological imaging technique. FDG-PET/CT has been used in the initial diagnosis, staging, and detection of recurrence in HNSCC. FDG-PET/CT has a higher sensitivity than conventional imaging methods to detect stage of disease accurately. Thus, the role of FDG-PET/CT is increasing in our clinical practice.

The maximum standard uptake of value (SUVm), a semi-quantitative measurement of tumor FDG uptake and enhanced uptake of FDG has been related to aggressive behaviour and less favorable results in many different tumor types such as lung and esophageal cancer (Swisher et al., 2004 ; Kee et al., 2010). Moreover, SUVm may be related with clinicopathologic features of the tumor in HNSCC. Pretreatment FDG uptake may also have evaluated as a prognostic and predictor factor with HNSCC. We aimed the prognostic utility of measuring FDG uptake in HNSCC prior to treatment with our retrospective experience.

<sup>1</sup>Department of Medical Oncology, Atatürk Education and Research Hospital, <sup>2</sup>Department of Medical Oncology, <sup>3</sup>Department of Nuclear Medicine, <sup>4</sup>Department of Public Health, Gazi University Faculty of Medicine, Ankara, Turkey \*For correspondence: drumutdemirci@gmail.com

## Materials and Methods

### Patients

Between February 2004 and July 2010, 64 patients who were diagnosed HNSCC underwent pretreatment FDG-PET/CT at the Department of Medical Oncology, Gazi University Hospital. FDG-uptake was assessed the SUV<sub>m</sub>. All patients who underwent evaluation also underwent systematic staging after direct laryngoscopy and tissue biopsy diagnosis with chest radiograph, serum chemistry, a contrast-enhanced computerized tomography (CT) or magnetic resonance imaging (MRI), and FDG-PET/CT imaging of the head and neck. Patients with distant metastases were not included in this series. We used the Tumor- node- metastasis (TNM) classification of the AJCC (7th ed) (Edge et al., 2010). Thirtythree (51%) of them had pre- and after treatment FDG-PET/CT imaging. At the each visit, routine clinical examination and blood chemistry were performed.

All treatment was performed with curative intent and consisted of definitive RT with or without chemotherapy or definitive resection with or without adjuvant RT. After completion of treatment, patients underwent routine surveillance every three months. All patients gave informed consents for each examination and treatment. 18F-FDG PET/CT Imaging

Whole body FDG-PET/CT data were acquired 60 minutes following the administration of FDG-PET/CT (0.10 mCi/kg of body weight) using a Discovery ST PET-CT scanner (GE Medical Systems, Milwaukee, Wisconsin, USA). Patients had fasted for at least 6 hours and their blood glucose levels were controlled before 18F-FDG injection. All of the patients had blood glucose levels lower than 160 mg/dl. No intravenous contrast material was used for the CT scans. During the uptake phase of 18F-FDG patients laid still in a warm room. Each patient underwent a low dose (120 kV, 10-90 mA) whole body CT scan and subsequently a 3D whole body PET scan with an acquisition time of three minutes per bed position. The resulting axial, coronal and sagittal slices were visually evaluated by two nuclear medicine physicians experienced in whole body FDG-PET/CT imaging.

### Quantitative Analysis of 18F-FDG PET-CT Data

Metabolic activities of any lesion with a visually abnormal FDG uptake (uptake greater than its surrounding soft tissues) were analyzed using standardized uptake values (SUV). SUV is a commonly applied semi-quantitative parameter to express tumor FDG uptake. It is calculated by normalizing the radioactivity concentration in tissue for patient weight and injected radioactivity. In order to minimize partial volume effects maximum SUV (SUV<sub>max</sub>) was preferred over mean SUV. SUV<sub>max</sub> was calculated separately for the primary lesion and each abnormal lymph node. For nodal disease, the highest SUV<sub>max</sub> was used for subsequent correlation with clinical outcomes.

### Statistics

All statistical analyses were performed using SPSS version 16.0 (SPSS, Chicago, IL). The significances of

differences between two categories were established using Mann-Whitney U testing. We dichotomized the clinical features for subsequent univariate and regression analysis. Also the therapeutic effects were evaluated by pre-treatment SUV<sub>m</sub> and % change in SUV. We calculated the percent change in SUV (%change SUV) as follows:  $100 \times (\text{pre-treatment SUV}_m - \text{posttreatment SUV}_m) / \text{pre-treatment SUV}_m$ . Because of the limited number of disease events, we specifically chose to create a Cox regression analysis of DFS and OS hazard ratios.

## Results

All patients (n=64) who underwent evaluation pretreatment FDG-PET/CT imaging and 34 had pre- and after treatment FDG-PET/CT imaging. Median age was 58 (range: 16-87) in total 64 patients, 13 women (20.3%), 51 man (79.7%). Tumor sites are nasopharynx (n= 29, 45.3%), larynx (n= 16, 25%), oropharynx (n= 13, 20.4%) and hipopharynx (n= 6, 9.4%) Most patients (54 of 64) (84.4%) had stage III/IV, the remaining 10 patients (15.6%) had stage I/II disease. Forty-four patients (68.8%) had T3,4 disease. .

Sixty patients were scheduled to receive definitive RT. Fiftyseven patients were treated CCRT (69.9 to 70.0 Gy), 40 were concurrent with cisplatin-docetaxel, 17 were cisplatin. While three with early-stage disease were treated only radiotherapy at doses of 60.0 to 70.0 Gy, four patients were not treated RT. Surgery (definitive resection with or without neck dissection) were performed in 15 patients (23,4%).

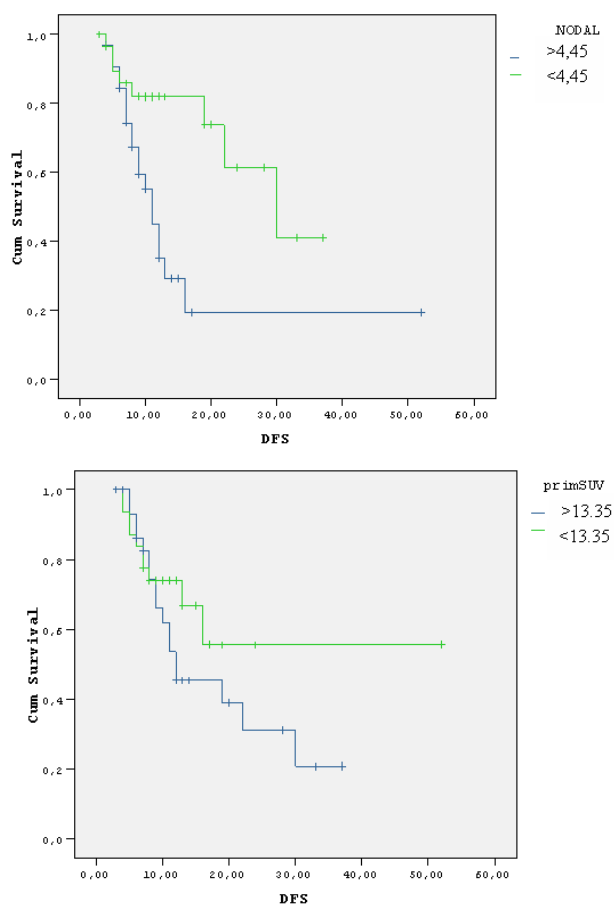
Induction chemotherapy (TCF; docetaxel- cisplatin-5FU) was performed in four patients with advanced primary tumor (T4) because of constrict to radiation field. After CCRT, three cycles of different regimen (cisplatin-docetaxel or TCF) in were performed like adjuvant intend in locally advanced NPC. All patients were eligible analysis in this study. Objective response rate was 78.2 % [38 complete response (CR), 12 partial response (PR)]. One patient had stable disease. Thirteen patients (20.3%) were progressed (PD).

The median primary SUV<sub>m</sub> in our series was 13.35 (range, 4.8–33.1). The median nodal SUV<sub>m</sub> in our series was 4.45 (range, 0–25.6). Median % change in SUV<sub>m</sub> was 74.09 (range, -61–100). Primary tumor SUV<sub>m</sub> was associated with T stage (p=0,048), but not stage of disease (p= 0,465). Nodal SUV<sub>m</sub> was no associated with either T stage (p= 0,525) or stage of disease (p= 0,340).

As shown in Table 1, in univariate analysis there was no correlation between DFS and study parameters that are

**Table 1. Univariate Log-rank Testing of Clinical Features for DFS and OS (Mann Whitney U)**

		DFS	OS
Primary	SUV <sub>m</sub> <13,45/>13,45	0.861	0.152
Nodal	SUV <sub>m</sub> <4,45 />4,45	0.067	0.686
Stage	I-II /III-IV	0.12	0.014
T stage	I-II/ III-IV	0.037	0.003
Surgery	No/Yes	0.037	0.651
Age	60<60>	0.07	0.6
Sex	Man/ woman	0.125	0.953



**Figure 1. Disease Free Survival by Kaplan-Meier.** Upper: primary tumor SUVm of 13.4 or greater ; Lower: dichotomized nodal SUVm greater or less 4.45

primer SUVm (<13.4 vs  $\geq 13.4$ ,  $p = 0,861$ ), nodal SUVm (<4.45 vs  $\geq 4.45$ ,  $p = 0,067$ ), % change in SUVm (<74.09 vs  $\geq 74.09$ ,  $p = 0,127$ ), age (<60y vs  $\geq 60y$ ,  $p = 0,07$ ), surgery (yes vs no,  $p = 0,037$ ), sex ( $p = 0,125$ ), T (T1/2 vs T3/4,  $p = 0,037$ ), stage (St1/2 vs St3/4,  $p = 0,12$ ). Statistically significant correlation found between surgery and T stage ( $p < 0.05$ ). In univariate analysis there was no correlation between OS and study parameters that are primer SUVm (<13.4 vs  $\geq 13.4$ ,  $p = 0,152$ ), nodal SUVm (<4.45 vs  $\geq 4.45$ ,  $p = 0,686$ ), % change in SUVm (<74.09 vs  $\geq 74.09$ ,  $p = 0,127$ ), age (<60y vs  $\geq 60y$ ,  $p = 0,750$ ), surgery (yes vs no,  $p = 0,651$ ), sex ( $p = 0,953$ ), T (T1/2 vs T3/4,  $p = 0,003$ ), stage (St1/2 vs St3/4,  $p = 0,014$ ). Statistically significant correlation found between stage and T stage ( $p = 0.001$ ).

Multivariate analysis showed that nodal SUV ( $p = 0.036$ ), with a hazard ratio (HR) of 0.338 (95% CI: 0.123-0.93) and surgery ( $p = 0.021$ ), with a hazard ratio (HR) of 3.246 (95% CI: 1,19-8,85) remained significant predictors of DFS. There was no statistical significance for other factors.

## Discussion

FDG-PET/CT has been shown to be an effective imaging methods for staging work-up (Kresnik et al., 2001; Murakami et al., 2007) also treatment was altered in 31% of patients with HNSCC by FDG-PET/CT (Fleming et al., 2007). Recent studies showed that a correlation with FDG uptake and biologic fetatures of tumors such

as proliferation, hypoxia and poor clinical outcomes in HNSCC (Couture et al., 2002; Burgman et al., 2001; Bos et al., 2002).

Current study involved a remarkable number of previously untreated HNSCC patients those with treated different combination of treatment modality, either surgery followed by adjuvan RT and/or chemotherapy, induction chemotherapy, curative RT or CCRT, and salvage surgery. We have investigated that FDG uptake in patients with HNSCC is correlated with prediction (tumor response) and prognosis (survival). Also nearly half of patients had pre and post FDG-PET/CT imaging. Advanced tumors (T3-4) and stage (stage III/IV) generally tend to have higher SUVm (Halfpenny et al., 2002; Allal et al., 2004). We showed that primary tumor SUVm was associated with T stage. Recent studies found that a pretreatment primary tumor SUVm of 5.5 to 12.0 or greater predicted inferior response to treatment, local disease control, and poor survival outcome in patients with HNSCC, including both surgical and non-surgical series (Minn et al., 1997; Halfpenny et al., 2002; Allal et al., 2004; Kim et al., 2008; Inokuchi et al., 2011). In contrast with these previous studies, we showed that primary tumor SUVm and % change in SUVm were not prognostic or predictive. Similary our findings, there was no role for pretreatment SUVm as a predictor of CCRT outcome in HNSCC in recent retrospective and prospective studies (Schinagl et al., 2011; Roh et al., 2007). However nodal SUVm correlated with DFS. Nodal SUVm may be used to select patients for intensive treatments. In a recent retrospective study, Yao et al. (2009) examined 177 patients who had FDG PET scans before treatment. Most frequently most patients had locally advanced tumors and a median pre-treatment primary SUVm of 10.65 (range: 2.6-48.2) and a median pre-treatment nodal SUVm of 7.33 (range: 1.5-33.1). Primary SUVm was found to be significantly associated with DFS and OS. Nodal SUVm was significantly associated with distant metastasis.

In a study showed that a significant difference was found between the recurrent and non-recurrent cases regarding the post-treatment SUVm (<3 vs >3) and the % change in SUVm (<60 vs >60) the overall accuracy was 88.2% (45/51). They concluded that analysis of the post-treatment SUVm and the % change in SUVm were useful to predict the prognosis after CCRT (Hoshikawa et al., 2009). However we did not found similar association with between % change in SUVm and survival.

We suggested that nodal SUVm is corralated with poorer outcome thus these patients should have more aggressive treatment combinations. FDG-PET/CT was evaluated for individualized therapy in HNSCC with two recent studies. Roh et al (2007) showed that SUVm was an independent prognostic factor for survival. They concluded that primary surgery followed by adjuvant RT and chemotherapy prolonged survival than by primary organ preservation strategy with CCRT in high SUVm. In Sang Yoon Kim et al study (2008), local disease control and survival outcomes were generally higher in the surgery group than those in the RT group, and this difference was significant in patients with a high (6.0) tumor SUVm but not in those with a low (<6.0) tumor SUVm. They

concluded that patients with high tumor FDG uptake may have improved survival with early surgical intervention followed by RT. Primary RT or CRT may be optional only in patients with low FDG uptake who hope to avoid surgery and postoperative morbidity.

The disadvantage of present study is a retrospective study, there may be potential biases especially in different tumor site and treatment combinations, those can affect association SUV<sub>m</sub> and treatment outcomes.

High SUV<sub>m</sub> is associated with a controversial results in previous studies however our results suggest that pretreatment nodal FDG uptake correlated with treatment outcome in patients with HNSCC. We need to be determined by further prospective research that a potential role for FDG-PET/CT as guidance for the primary treatment modality of patients with HNSCC who undergo more homogeneous study design.

## References

- Allal AS, Slosman DO, Kebdani T, et al (2004). Prediction of outcome in head-and-neck cancer patients using the standardized uptake value of 2-[18F]fluoro-2- deoxy-D-glucose. *Int J Radiat Oncol Biol Phys*, **59**, 1295-300.
- Bos R, van Der Hoeven JJ, van Der Wall E, et al (2002). Biologic correlates of 18 fluorodeoxyglucose uptake in human breast cancer measured by positron emission tomography. *J Clin Oncol*, **20**, 379-87.
- Burgman P, O'Donoghue JA, Humm JL, Ling CC (2001). Hypoxia-induced increase in FDG uptake in MCF7 cells. *J Nucl Med*, **42**, 170-5.
- Couture C, Raybaud-Diogene H, Tetu B, et al (2002). p53 and Ki-67 as markers of radioresistance in head and neck carcinoma. *Cancer*, **94**, 713-22.
- Edge SE, Byrd DR, Compton CC, et al eds (2010). *AJCC cancer Staging Manual*. 7th ed. New York: Springer.
- Fleming AJ Jr, Smith SP Jr, Paul CM, et al(2007). Impact of [18F]-2-fluorodeoxyglucose-positron emission tomography/computed tomography on previously untreated head and neck cancer patients. *Laryngoscope*, **117**, 1173-9.
- Forastiere AA, Goepfert H, Maor M, et al (2003). Concurrent chemotherapy and radiotherapy for organ preservation in advanced laryngeal cancer. *N Engl J Med*, **349**, 2091-8.
- Halfpenny W, Hain SF, Biassoni L, et al(2002). FDG-PET. A possible prognostic factor in head and neck cancer. *Br J Cancer*, **86**, 512-6.
- Hoshikawa H, Mitani T, Nishiyama Y, et al(2009). Evaluation of the therapeutic effects and recurrence for head and neck cancer after chemoradiotherapy by FDG-PET. *Auris Nasus Larynx*, **36**, 192-8.
- Inokuchi H, Kodaira T, Tachibana H, et al(2011). Clinical usefulness of [18F] fluoro-2-deoxy-D-glucose uptake in 178 head and-neck cancer patients with nodal metastasis treated with definitive chemoradiotherapy: consideration of its prognostic value and ability to provide guidance for optimal selection of patients for planned neck dissection. *Int J Radiat Oncol Biol Phys*, **79**, 747-55.
- Jemal A, Siegel R, Xu J, et al(2010). Cancer statistics, 2010. *CA Cancer J Clin*, **60**, 277-300.
- Kee F, Erridge S, Bradbury I, et al(2010). The value of positron emission tomography in patients with non-small cell lung cancer. *Eur J Radiol*, **73**, 50-8.
- Kim SY, Roh JL, Kim JS, et al(2008). Utility of FDG PET in patients with squamous cell carcinomas of the oral cavity. *Eur J Surg Oncol*, **34**, 208-15.
- Kresnik E, Mikosch P, Gallowitsch HJ, et al, (2001). Evaluation of head and neck cancer with 18F-FDG PET: a comparison with conventional methods. *Eur J Nucl Med*, **28**, 816-21.
- Minn H, Lapela M, Klemi PJ, et al(1997). Prediction of survival with fluorine-18-fluoro-deoxyglucose and PET in head and neck cancer. *J Nucl Med*, **38**, 1907-11.
- Monnerat C, Faivre S, Temam S, et al(2002). End points for new agents in induction chemotherapy for locally advanced head and neck cancers. *Ann Oncol*, **13**, 995-1006.
- Murakami R, Uozumi H, Hirai T, et al (2007). Impact of FDG-PET/CT imaging on nodal staging for head-and-neck squamous cell carcinoma. *Int J Radiat Oncol Biol Phys*, **68**, 377-82.
- Pignon JP, le Maître A, Maillard E, et al(2009). Meta-analysis of chemotherapy in head and neck cancer (MACH-NC): an update on 93 randomised trials and 17,346 patients. *Radiother Oncol*, **92**, 4-14.
- Roh JL, Pae KH, Choi SH, et al (2007). 2-[18F]-Fluoro-2-deoxy-D-glucose positron emission tomography as guidance for primary treatment in patients with advanced-stage resectable squamous cell carcinoma of the larynx and hypopharynx. *Eur J Surg Oncol*, **33**, 790-5.
- Schinagl DA, Span PN, Oyen WJ, et al (2011). Can FDG PET predict radiation treatment outcome in head and neck cancer? Results of a prospective study. *Eur J Nucl Med Mol Imaging*, 2011 Apr 2. [Epub ahead of print]
- Swisher SG, Erasmus J, Maish M, et al (2004). 2-Fluoro-2-deoxy-D-glucose positron emission tomography imaging is predictive of pathologic response and survival after preoperative chemoradiation in patients with esophageal carcinoma. *Cancer*, **101**, 1776-85.
- Urba S, Wolf G, Eisbruch A, et al (2006). Single-cycle induction chemotherapy selects patients with advanced laryngeal cancer for combined chemoradiation: a new treatment paradigm. *J Clin Oncol*, **24**, 593-8.
- Yao M, Smith RB, Hoffman HT, et al (2009). Clinical significance of postradiotherapy [18F]-fluorodeoxyglucose positron emission tomography imaging in management of head-and-neck cancer-a long-term outcome report. *Int J Radiat Oncol Biol Phys*, **74**, 9-14.