

## RESEARCH COMMUNICATION

# Extended Full-thickness Transanal Local Excision to Treat Ultra-low Rectal Cancer: an Initial Clinical Exploration

Xin Zhou<sup>1#</sup>, Xin-En Huang<sup>2#</sup>, Tong Zhang<sup>3</sup>, Jun-Qing Shang<sup>1</sup>, Xin Guan<sup>1</sup>, Jian Zhong<sup>1</sup>, Bo Feng<sup>1</sup>, Yue Sun<sup>4</sup>, Jian-Nong Zhou<sup>1\*</sup>

### Abstract

**Objective:** To investigate the feasibility of extended full-thickness transanal local excision for rectal cancers invading anorectal junction. **Methods:** Four patients with small (size  $\leq 3$ cm) unfixed rectal cancer, which extended into the upper anal canal, were submitted to transanal local excision with a dissection plane extended to the striated muscle layer around the upper anal canal, so that a portion of striated muscle beneath or around the tumor was excised en bloc with the anorectal wall. The defect in the anorectal wall was laid open to granulate and epithelize. **Results:** The mean operative time was  $28 \pm 6$  min, with no related mortality. Postoperative pathological examination confirmed clear resection and revealed 1, T2, 2, T1, and 1 Tis carcinomas. The median follow-up was 3.2 months (range, 1.5-13.0 months). Minor soiling with flatus incontinence was common during the first postoperative month. Two patients with a follow-up longer than 3 months had perfect anal continence. No local recurrence was observed. **Conclusion:** Extended full-thickness transanal local excision for rectal tumors lying at the anorectal junction is safe and simple. Patients with partial excision of striated muscle around the upper anal canal may still enjoy good anal continence. Further studies on extended full-thickness transanal excision are worthwhile.

**Keywords:** Extended transanal local excision - rectal cancer - anorectal function - incontinence

*Asian Pacific J Cancer Prev*, **12**, 1045-1048

### Introduction

Transanal local excision is an acceptable curative operation for selected small low-risk T1 low rectal cancer (Blackstock et al., 2010; You et al., 2007). Recently increasing evidence has implied that preceded by adjuvant chemoradiotherapy transanal local excision may be an alternative curative procedure for small T2 and even T3 low rectal cancer that responds well to neoadjuvant therapy (Bujko et al., 2007; Park et al., 2007; Borschitz et al., 2008; Lezoche et al., 2008; Callender et al., 2010). For those who can not tolerate radical resection and those who do not accept colostomy, transanal local excision can serve as a palliative operation.

For ultra-low rectal cancer that invading the anorectal junction with tumor infiltrating upper anal canal, the anorectal wall beneath is wrapped by little or no mesorectal tissue. In this circumstance conventional full-thickness resection will has a limited deep radial resection margin, which may be insufficient for tumors infiltrating deep into or out of the longitudinal muscle. We have performed extended full-thickness transanal local excision which extended the dissection plane from the intersphincteric plane to the striated musculature layer.

This article reports the preliminary clinical and functional results of this new procedure.

### Materials and Methods

From January 2010 to January 2011, four patients (2 females; age, 56–73; mean,  $64 \pm 8$  years) with pathologically confirmed small (diameter, 1.8-2.5cm, mean  $2.1 \pm 0.3$ cm) well-differentiated non-colloid rectal adenocarcinoma or adenocarcinoma in situ were recruited to receive a new transanal local excision with a curative intention. Preoperatively, all four patients had no symptoms associated with anal continence. Digital examination suggested tumors all infiltrated downwards into the upper surgical anal canal (below the upper edge of the puborectalis muscle) and were unfixed. On proctoscopy examination, the tumors were located in the posterior or posterolateral anorectal wall with an inferior margin at 2.5 to 4.5 cm from the anal verge (mean,  $3.5 \pm 0.9$  cm) and at 1.0 to 1.2 cm above from the dentate line. Pelvic magnetic resonant imaging with phased-array body coil revealed infiltration of mucosa or submucosa in 3 patients and superficial internal anal sphincter in 1 patient. Chest, abdominal and pelvic CT scan found no evidence

<sup>1</sup>Colorectal Cancer Center, <sup>2</sup>Department of Chemotherapy, <sup>3</sup>Department of Pathology, Jiangsu Cancer Hospital and Research Institute, Nanjing, <sup>4</sup>Department of Surgery, XinYi Hospital of Traditional Chinese Medicine, XinYi, Jiangsu, China #Co-first authors \*For correspondence: jiannz@yeah.net

of metastatic lesions. Two male patients chose local excision for desperate refusal of colostomy and two female patients for senile and frail habitus. All patients offered informed consent before surgery, concerning higher risk of recurrence after local excision and possible impairment of anal continence after extended local excision. All surgical protocols were approved by ethnic committee of Jiangsu Cancer Hospital and Research Institute.

### Operative Procedure

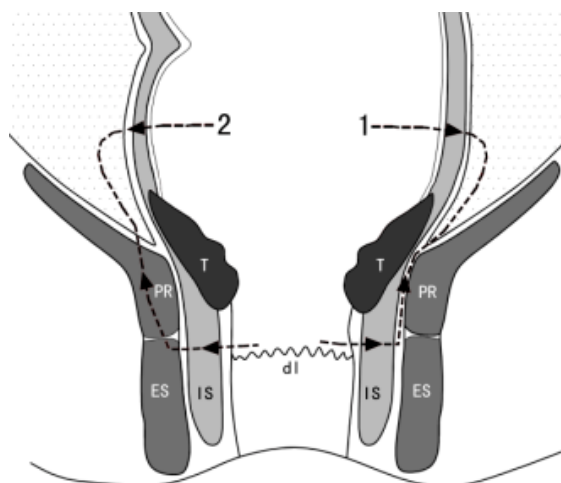
Surgery was undertaken under general anesthesia and routine antibiotic cover, preceded by thorough bowel preparation. The patient was placed in the lithotomy position. The anorectum was irrigated with 250 ml of 0.25% iodophor to clear the possible residual feces before the anal canal was gently dilated to accommodate four fingers. Anal retractors were then inserted to display the tumor. The rectum proximal to the tumor was packed to prevent stools or mucus intruding the operative field. A series of dots were made by using diathermy 1 cm away from the tumor edge to mark the resection margin. Incision was commenced from the lower margin which was at or within 0.5 cm above from the dentate line. The anal mucosa, submucosa, internal sphincter, and the longitudinal muscle were incised along the lower half of dotted markers, using electrocautery, and the striated muscle beneath was displayed. The incision was advanced about 2-3 mm deeper into the striated muscle. Then the lower resection margin was retracted upward and sharp and blunt dissection proceeded upward within the layer of striated muscle, then into the lower mesorectum by using ultrasonic scalpel. Finally the upper half dividing was conducted along the dotted markers. After the tumor was excised, hemostasis was secured and the surgical field was irrigated with another 250 ml of 0.25% iodophor to prevent tumor implanting. The residual striated muscle band exposed directly at the bottom of anorectal wall defect was reconstructed by plicating sutures while the anorectal wall defect was laid open to granulate and epithelize.

### Postoperative Care

Antibiotic cover was continued until postoperative day 3. Liquid diet was prescribed after first passage of flatus until postoperative day 7. From the second postoperative week the patient was gradually transitioned to low-fiber diet. Any anal squeezing or straining was forbidden during the first two postoperative weeks. Gentle laxative was used on requirement to avoid anal straining.

### Follow-Up and Functional Assessment

Follow-up examinations were arranged at 1 month after surgery then every 3 months. Examinations included digital examination, proctoscopy, and serum carcinoembryonic antigen and carbohydrate antigen 19-9 levels. Abdominal and chest CT was arranged 1 year after surgery or on clinical suspicion of recurrence. Anal function was assessed at the same time by using functional questionnaire, which inquired about stool frequency (number of bowel movements per 24 hours), feces and flatus discrimination, urgency (ability to defer



**Figure 1. Comparison between Conventional and Extended Full-thickness Local Excision for a Tumor Extending into the Upper Anal Canal.** 1) Conventional resection line; 2) Extended resection line; IS, internal sphincter; ES, external sphincter; PR, puborectalis muscle; dl, dentate line; T, tumor

stool evacuation for >15 minutes), fragmentation (more than 2 evacuations in 1 hour), soiling during the day and night, use of pads, use of medications, and alimentary restriction. Fecal incontinence was assessed by Kirwan classification.

### Results

The procedure was performed smoothly in four patients, with a mean operative time of  $28 \pm 6$  min (range, 20 to 35 minutes), encountering minimal bleeding of no more than 20 ml. There was no operative mortality or morbidity. Pathological examination demonstrated both negative mucosal and deep resection margins (5mm). Final pathological T staging was T2 in 1 patient, T1 in 2 patients, and Tis in 1 patient. All the tumors were well to moderately differentiated without colloid component. Neither vascular lymphatic invasion nor nerve infiltration was identified on pathological examination.

The median follow-up was 3.2 months (range, 1.5-13.0 months). No local recurrence was observed. Transient anal incontinence to flatus and minor soiling occurred in all four patients, which necessitated the use of pads. At one month after surgery, no anal incontinence except minor soiling was present. Two patients with a follow-up more than 3 months had perfect anal continence. Stool frequency was 1 to 3 times a day. The ability of feces and flatus discrimination was preserved in all patients. No patient complained urgency or fragmentation. All patients were satisfied with their anal function

### Discussion

The extended full-thickness transanal local excision described in this article in comparison with the conventional transanal local excision, had two major features. First, the dissection plane was advanced from the intersphincteric plane to the striated musculature layer. This modification entailed little technical difficulties as the dissection within

the soft loose striated muscular structure with the aid of ultrasonic scalpel was quite simple and met with little bleeding. The second modification was to lay the defect in the anorectal wall open, which not only made the procedure more simple by omitting the painstaking suture repair of the anorectal wall defect under limited exposure within confined operative field, but also circumvented the postoperative risk of anorectal dehiscence due to excessive suture tension, secondary hemorrhage, perirectal abscess arising from perianorectal collection of exudation or blood and unsatisfied drainage, and anorectal stricture. Thereby we carried out the procedure smoothly in 4 patients, with a remarkably short operative time of 20 to 35 minutes and little bleeding less than 20 ml. No operative mortality or postoperative complication occurred. Therefore we believe this modified local excision is technically simple and safe.

Although this extended local excision may be technically feasible, it may seem bold and controversial with regard to conventional concept that puborectalis muscle and deep anal external sphincter play a predominant role in maintaining anal continence and injury or operational dividing without proper repair of these muscles will inevitably lead to major anal incontinence (involving involuntary excretion of liquid or solid feces) (Rao 2004). Therefore it has almost become a surgical doctrine that whenever possible these muscles should not be excised or divided without proper repair. According anatomic and clinical studies, the upper anal canal above the dentate line is surrounded mainly by puborectalis muscle (Ayoub, 1979; Fucini et al., 1999; Rowe et al., 1974). We cut the anal wall at or within 0.5 cm above from the dentate line and thereby we have excised about one quarter of the circumference of puborectalis muscle with or without a small portion of deep external anal sphincter. Two major reasons have prompted us to break the surgical doctrine. First, the mesorectum terminates at the upper edge of puborectalis muscle and to enlarge the radial resection margin in the area of upper anal canal inevitably involves the excision of striated musculature which closely surrounds the anal wall.

Although preoperative MRI had indicated tumor infiltration no more than submucosa in three patients, during the operation we still suspected infiltration beyond submucosa. As these patients had refused to receive radical resection we tried to excise the lesions locally with sufficient radial as well as mucosal resection margin. And pathological examination had proved that we had achieved this aim in all four patients as sufficient (5mm) mucosal and deep radial margins were pathologically documented. The second reason was that there was increasing evidence from clinical studies suggesting that excision of puborectalis muscle with or without partial external anal sphincter did not necessitate major fecal incontinence. In 2002, Fucini et al (2002) reported that seven patients with low rectal cancer infiltrating puborectalis muscle were selected to undergo radical resection with excision of puborectalis muscle and partial internal anal sphincter and transanal reconstruction of intestinal continuity. After 3 years, six out of the seven patients were still alive and anal function was assessed.

None of the six patients had incontinence to solid stools. Two patients conserved normal anal continence, two had incontinence to flatus only, and two had occasional leakage of liquid stools.

The results of this pioneering study contradicted the conventional surgical doctrine that excision of puborectalis muscle would lead to major anal incontinence. In addition, several Japanese surgical teams had even gone further as to excise both the puborectalis muscle and partial external anal sphincter in combination with total or subtotal internal anal sphincter. About 65% of these patients with closure of covering stoma retained good or acceptable anal continence, with 35% complaining major soiling (Ito et al., 2009; Saito et al., 2004; Shirouzu et al., 2003). Being aware of these research results, and that local excision does less damage to rectal accommodation and reservoir function than radical resection, we hypothesized that extended local excision would not lead to major incontinence. In concordance with our hypothesis, none of the four patients undergoing extended local excision suffered from major incontinence. Our preliminary results suggest that perfect anal continence or good anal continence with minor soiling can be anticipated after extended local excision.

For future studies, the indication for this extended local excision needs further consideration. Theoretically, for T1 low rectal cancer, conventional full-thickness excision would be proper to attain sufficient deep radial resection margin. As for T2 and T3 rectal cancers that are about to or have already penetrated the internal anal sphincter and longitudinal muscle, by using this extended local excision, sufficient resection margin can be achieved. Currently local excision is recommended to patients with T2 or T3 rectal cancer not as curative surgery, but palliative surgery (Blackstock et al., 2010; You et al., 2007). However, mounting evidence from retrospective studies have suggested that T2 or T3 rectal cancer downstaged to T0 or T1 may come out with a good oncological result comparable to those undergoing radical resection (Callender et al., 2010; Borschitz et al., 2008; Bujko et al., 2007; Park et al., 2007). A small randomized clinical trial conducted by Lezoche et al (2008) has even proved that in patients with small T2 low rectal cancer local excision preceded by adjuvant chemoradiotherapy can achieve good oncological results as good as radical resection involving total mesorectal excision. Therefore, with the wide spread of preoperative adjuvant chemoradiotherapy, local excision in the future may play a more important role in the surgical treatment of T2 and T3 low rectal cancer. Consequently the extended local excision described here may expect a wide application.

In this article, we described a new procedure denoted as extended transanal local excision. Our initial experience with this procedure in four patients with extremely low rectal cancer demonstrated that it was technically simple and perfect or good anal function could be anticipated after this procedure. Oncologically this procedure may ensure the attainment of sufficient deep radial resection margin and may potentially have a remarkable role in the surgical treatment of T2 and T3 ultra-low rectal cancer. Further studies are now needed to define its full impact

on anal function and potential role in the treatment of low rectal cancer.

## Acknowledgments

This study was fully supported by Medicine Research Fund, Faculty of Medicine, Chiang Mai University, Chiang Mai, Thailand.

## References

- Ayoub SF (1979). Anatomy of the external sphincter in man. *Acta Anat*, **105**, 25-36.
- Blackstock W, Russo SM, Suh WW, et al (2010). ACR Appropriateness Criteria: local excision in early-stage rectal cancer. *Curr Probl Cancer*, **34**, 193-200.
- Borschitz T, Wachtlin D, Möhler M, et al (2008). Neoadjuvant chemoradiation and local excision for T2-3 rectal cancer. *Ann Surg Oncol*, **15**, 712-20.
- Bujko K, Sopylo R, Kepka L (2007). Local excision after radio(chemo)therapy for rectal cancer: is it safe? *Clin Oncol (R Coll Radiol)*, **19**, 693-700.
- Callender GG, Das P, Rodriguez-Bigas MA, et al (2010). Local excision after preoperative chemoradiation results in an equivalent outcome to total mesorectal excision in selected patients with T3 rectal cancer. *Ann Surg Oncol*, **17**, 441-7.
- Fucini C, Elbetti C, Messerini L (1999). Anatomic plane of separation between external anal sphincter and puborectalis muscle: clinical implications. *Dis Colon Rectum*, **42**, 374-9.
- Fucini C, Elbetti C, Petrolo A, et al (2002). Excision of the levator muscles with external sphincter preservation in the treatment of selected low T4 rectal cancers. *Dis Colon Rectum*, **45**, 1697-705.
- Ito M, Saito N, Sugito M, et al (2009). Analysis of clinical factors associated with anal function after intersphincteric resection for very low rectal cancer. *Dis Colon Rectum*, **52**, 64-70.
- Lezoche G, Baldarelli M, Guerrieri M, et al (2008). A prospective randomized study with a 5-year minimum follow-up evaluation of transanal endoscopic microsurgery versus laparoscopic total mesorectal excision after neoadjuvant therapy. *Surg Endosc*, **22**, 352-8.
- Park C, Lee W, Han S, et al (2007). Transanal local excision for preoperative concurrent chemoradiation therapy for distal rectal cancer in selected patients. *Surg Today*, **37**, 1068-72.
- Rao SSC (2004). Pathophysiology of adult fecal incontinence. *Gastroenterology*, **126**, S14-22.
- Rowe JS, Skandalakis JE, Gray SW, et al (1974). The surgical anal canal. *Contemp Surg*, **5**, 107-17.
- Saito N, Ono M, Sugito M, et al (2004). Early results of intersphincteric resection for patients with very low rectal cancer: an active approach to avoid a permanent colostomy. *Dis Colon Rectum*, **47**, 459-66.
- Shirouzu K, Ogata Y, Araki Y, et al (2003). A new ultimate anus-preserving operation for extremely low rectal cancer and for anal canal cancer. *Tech Coloproctol*, **7**, 203-6.
- You YN, Baxter NN, Stewart A, et al (2007). Is the increasing rate of local excision for stage I rectal cancer in the United States justified? A nationwide cohort study from the National Cancer Database. *Ann Surg*, **245**, 726-33.