

RESEARCH COMMUNICATION

A Clinicopathologic Study of Breast Lumps in Bhairahwa, Nepal

Rajendra Kumar

Abstract

Background: Various types of lesion from inflammation to carcinoma can affect the breast. Some lesions are common in young females while others are more common in elderly age group. Early presentation and prompt diagnosis is essential to relieve anxiety of non-neoplastic conditions, and in case of carcinoma, it can save the patient from metastases. Many cases related to breast lesions from the region are reported in the surgery clinics of this institute and various breast diseases are being managed in the clinical departments. Analysis of pattern and prevalence should provide a valuable guideline for clinicians in Nepal for comparison with other countries. **Methods:** In the retrospective clinical study during a 9 year period, cases of breast lesions and lumps underwent fine needle aspiration cytology and Pap staining was done in alcohol fixed smears. A total of 65 doubtful cases were diagnosed through histopathological examinations by conventional methods. All those with undetermined and inconclusive material were excluded from the study. **Results:** In the study of total 243 cases, inflammatory conditions 22.6%, fibrocystic change 41.2%, fibroadenoma 21.8%, other benign breast disease 4.5%, gynaecomastia 2.5% and carcinoma 7.4% were detected. **Conclusion:** Fibrocystic change was the commonest lesion in this study with 33 years as the average age of presentation. However, malignancy was detected above 40 years of age.

Keywords: Breast carcinoma - fibroadenoma - fibrocystic change - gynaecomastia

Asian Pacific J Cancer Prev, 11, 855-858

Introduction

Breast is a glandular organ influenced by hormones in females with various structures giving rise to different types of lesion and lumps. Inflammatory lesions, common in lactating group of females, are not as much frequent as non-inflammatory conditions. Benign tumors in young adults have higher incidence. Inflammatory and some benign lesions like fibrocystic change and fibroadenoma are managed adequately with excellent outcome.

However, proliferative changes can sometimes transform into malignancy which imparts importance of accurate diagnosis and treatment. Malignant neoplasm is more frequent in old females like other conditions of cancer and it is equally prevalent in Nepal as in other parts of the world (Khan et al., 2003). In Nepal, breast carcinoma is the second most common malignancy among females after carcinoma cervix and a multi-institution hospital-based study on cancer incidence observed a shift in relatively younger ages (Pradhananga et al., 2009). Delay in presentation and diagnosis causes direct as well as distant metastasis leading to complicated management as most of them usually present in advanced stage of disease (Mayun et al., 2008). Mammography is a useful investigation to detect breast carcinoma but chance of missing carcinoma persists in few cases, moreover, it

is available at selected centers in Nepal (Sidharth et al., 2008). In the present set up also, there is no facility of mammography. Patients above 30 years with lump of breast should consult and be screened for cancer (Osime and Ohanaka, 2008). Competitive life and urban strain are also contributing breast lesions as common problem in females especially adults. They are more among single females of high status group employed in professional occupations (Fleming et al., 1982).

Breast lesions were analyzed in various parts of Nepal by scientists. Most of them revealed non-neoplastic breast lesions as the commonest (Khan et al., 2003; Tiwari, 2007; Pradhan & Dhakal, 2008). Many cases related to breast lesions from the region are reported in the surgical clinics of this institute. Various breast diseases are being managed in the hospital. In the present setup retrospective study was undertaken to find out the pattern and frequency of lesions including malignancies affecting breast with intention that clinicians of this region can be responsive of its incidence.

Materials and Methods

In the retrospective study, the patients consulted at outdoor clinics of the Universal College of Medical Sciences Teaching Hospital (UCMSTH) starting from 2000 to December 2008 where all history taking, clinical

examination, investigations and surgical interventions were done. In the cases bearing breast lesions and lumps, fine needle aspiration biopsy was done. The diagnosis in doubtful cases was confirmed by histopathological examination of biopsy specimen, consisting of 65 cases, in the Department of Pathology of UCMSTH. The pap staining was done in alcohol fixed smear of aspiration cytology and histopathological examination was done after conventional method of fixation, processing and staining with routine hematoxylin & eosin. The slides of all the cases were reviewed with the help of hospital records based on the diagnostic criteria of Steven G Silverberg (1983). These were analyzed on the basis of age especially above and below 30 years, gender, location and type of lesions. All other cases with undetermined diagnosis and inadequate material were kept aside and excluded from the study. There was no history of radiation exposure in any case. We applied t-Test to assess the distribution of variables observed in this study.

Results

In the retrospective study of breast lesions during 9 years period, finally 243 cases were distinguished after exclusion of 21 undefined cases. The age group of the cases is shown in Table 1.

The age of the cases ranged 6-72 years. Pain and tenderness was observed in almost all inflammatory cases. The average age of presentation was analyzed 34 years. It includes 10 male cases as well. This shows maximum no. of cases was seen in 21-30 years followed by 31-40 years. There were 125 left, 104 right and 14 cases of bilateral breast involvement. It includes 15 cases of nipple discharge with one bloody, but none was detected of malignancy. The distribution of various lesions of breast is shown in Figure 1.

The inflammatory conditions (55 cases) included acute mastitis/abscess 35, granulomatous inflammation 8, fat

Table 1. Showing Cases in Different Age Group

Age group (years)	No. of patients
0-10	1
11-20	26
21-30	87
31-40	67
41-50	40
51-60	16
61-70	5
71-80	1
81-90	0
Total	243

Table 2. Showing Cases of Various Lesions in <30 & >30 Years Age

Type of lesions	<30 years	>30 years	Total
Inflammatory conditions	29	26	55
Fibrocystic change	42	58	100
Fibroadenoma	34	19	53
Benign breast diseases	4	7	11
Gynaecomastia	2	4	6
Carcinoma breast	0	18	18
Total	114	129	243

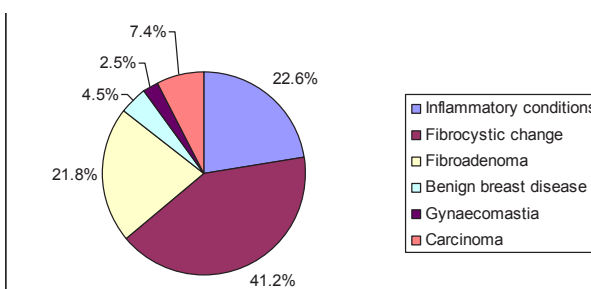


Figure 1. Showing Pattern and Distribution of Various Lesions of the Breast in the Present Study

necrosis 5, duct ectasia 3, galactocele 2 and organizing hematoma 2 cases. The average age was estimated 33 years. The granulomatous inflammations consisted one case of tuberculosis.

The study shows one hundred cases of fibrocystic change with 33 years as the average age of presentation. It includes cystic change 10, epithelial/ductal hyperplasia 30, fibroadenosis 36, fibrosis 20 and sclerosing adenosis 4. This includes 7 cases of atypical hyperplasia as well.

This is followed by 53 cases of fibroadenoma including three giant fibroadenoma in the average age of 27 years. Other benign lesions (11 cases) included adenoma 2, duct papilloma 7 and lipoma 2 cases. The average age for all benign breast disease was found to be 30 years. Atypical duct papilloma was observed in two cases and warning of periodical check up was advised to the patients.

The gynaecomastia were diagnosed in 6 male cases with average age of 37 in the range of 15-65 years. One case had enlargement of left breast for 3 ½ years. No case of malignancy was seen among males.

The carcinoma cases were found in 18 in the range of 40-72 with 54 years as the average age of presentation. There were 7 cases of invasive intraductal carcinoma one each of comedocarcinoma and scirrhous, and lymphadenopathy was detected in 3.

The inflammatory and fibrocystic changes were common around and slightly above 30 years respectively. Some of the lesions like fibroadenoma were found most common in below 30 years, whereas gynaecomastia in males and carcinoma in female breast were more common in older than 30 years as shown in Table 2.

The 10 male cases were of gynaecomastia 6, mastitis 2, benign cyst 1 and sclerosing fibrosis 1.

All the cases of nipple discharge were detected either of inflammatory or benign lesions.

The t-test on the results obtained in this series was significant at level of 0.05 among the age groups (t=2.55253, p=0.03404), lesions of cases (t=2.75706, p=0.03997) and average age of presentation of different lesions (t=10.21901, p=0.0001).

Discussion

The various studies in Nepal have revealed wide range of breast lesions. The breast abscess from 6 to 24%, fibrocystic change 5.5-49%, fibroadenoma 8-40% and malignancy 6.6-15.5 % (Khan et al., 2003; Tiwari, 2007; Pradhan & Dhakal, 2008). There were 96% females and 4% males in this study. In a study in Sudan by Ahmed et

al., (2010), they were 97 and 3 percent respectively. The age of the patients ranged 6-72 years in this study. In a study in Nepal by Tiwari (2007), they ranged 17-56 years. Right breast was involved in 51.4%, and left in 42.8 % in the present series. Ahmed et al., (2010) observed similar involvements in their study. It can be assumed that it may be due to physical and social grounds which play role in predominance of left sided involvement in the females. Nipple discharge was found in 6% cases, but none was associated with carcinoma. One case of bloody nipple discharge was encountered which was related to inflammatory condition. Nipple discharge is also related to inflammatory and benign conditions, and a literature reported this 20% (Ahmed et al., 2010). Breast diseases except carcinoma are manageable easily if diagnosed in time.

The inflammatory conditions were 22.6% in this series with majority of cases consisting of mastitis and abscess. This is similar to the findings from Saudi Arabia who observed acute mastitis/abscess 26.5% in their study (Nemengani and Yaqoob, 2009). Among the non-neoplastic conditions, mastitis and abscess were found to be painful clinically in most of the cases.

In this series non-neoplastic lesions were highest in proportion 90%, whereas neoplastic cases were only 7.4%. Inflammations and benign neoplasms formed major cluster of this series in agreement with a study by Osime and Ohanaka (2008).

Fibrocystic change consisted of approximately 41% in this study with average age 33 years, and fibroadenosis formed largest group followed by epithelial hyperplasia, having 7 cases of atypical type. In a study in Nepal by Pradhan and Dhakal (2008), it was found around 49%.

In a study of breast lump in Nepal by Khan et al., (2003), 61.7% benign breast conditions were observed. Among the benign breast diseases fibroadenoma accounted 22% in this series. It was analyzed the commonest benign breast lesion (23.7%) in a study by Mayun et al., (2008), as well among adolescent females with average age of 16 years in another study by Tea et al., (2009). Other lesions like adenoma, lipoma and duct papilloma were detected in few cases. Occasionally, cases of papilloma harbors malignancy. Intraductal papilloma especially multiple papilloma on core biopsy were diagnosed malignant on final histopathology and it represents a marker for breast cancer risk (Ali-Fehmi et al., 2003; Skandarajah et al., 2008). Atypical duct papilloma was seen in two cases in this study and till now no clinical features of aggressiveness have been observed. Malignancy was detected on final excisional biopsy in 25% cases of core biopsied benign/atypical lesion diagnosis by Arora et al., (2007). Multiplicity of benign breast lesions is also a risk factor for progression to breast cancer as observed by Cheng et al., (2008).

Malignant breast lesions are also common in Nepal, and are the second commonest malignant tumor among females (Khan et al., 2003; Pradhananga et al., 2009). It was found in 18 cases. Most of the cases were elderly females with average age of 54 years. There were 7 cases of invasive type and metastasis to lymph node was detected in 3 cases. One case of comedo pattern

A Clinicopathologic Study of Breast Lumps in Bhairahwa, Nepal and another case of scirrhous type was detected. It was observed upto 15.5% in a study of Pradhan and Dhakal, (2008) in Nepal. In a report from Nigeria, it was diagnosed approximately 40% by Mayun et al., (2008). However, mortality and incidence is relatively lower in developing countries and other parts of globe in comparison to western population (Khan et al., 2003).

Gynaecomastia is the commonest breast lesion among males. Rarely, papillary lesion also occurs and can range from papillary hyperplasia in gynaecomastia to invasive papillary carcinoma (Reid-Nicholson et al., 2006). This was found in six of 10 cases. No case of carcinoma was found in this study. In a study in Sudan, gynaecomastia was found 50% among males by Ahmed et al (2010). Overall this was 2.5% in this study; however, Khan et al (2003) from Nepal reported this 11.3%.

In conclusion, the analysis of this study reveals fibrocystic change as the commonest lesion common around 33 years of age. Investigations like fine needle aspiration biopsy and core biopsy can detect papilloma, multiple papilloma and atypical hyperplasia and play important role in detection and prevention of malignancy especially above 40 years, but excision biopsy is mandatory to rule out malignancy to be treated by surgical intervention.

References

- Ahmed HG, Ali AS, Almobarak AO (2010). Frequency of breast cancer among Sudanese patients with breast palpable lumps. *Ind J Cancer*, **47**, 23-6.
- Ali-Fehmi R, Carolin K, Wallis T, et al (2003). Clinicopathologic analysis of breast lesions associated with multiple papillomas. *Hum Pathol*, **34**, 234-9.
- Arora N, Hill C, Hoda SA, et al (2007). Clinicopathologic features of papillary lesions on core needle biopsy of the breast predictive of malignancy. *Am J Surg*, **194**, 444-9.
- Cheng J, Qiu S, Raju U, et al (2008). Benign breast disease heterogeneity: Association with histopathology, age, and ethnicity. *Breast Cancer Res Treat*, **111**, 289-96.
- Fleming NT, Armstrong BK, Sheiner HJ (1982). The comparative epidemiology of benign breast lumps and breast cancer in Western Australia. *Int J Cancer*, **30**, 147-52.
- Khan S, Kapoor AK, Khan IU, et al (2003). Prospective study of pattern of breast diseases at Nepalgunj medical college (NGMC). *Nepal Kathmandu Univ Med J*, **1**, 95-100.
- Mayun AA, Pindiga UH, Babayo UD (2008). Pattern of histopathological diagnosis of breast lesions in Gombe, Nigeria. *Niger J Med*, **17**, 159-62.
- Nemengani D, Yaqoob N (2009). Fine needle aspiration cytology of inflammatory breast lesions. *J Pak Med Assoc*, **59**, 167-70.
- Osime OC, Ohanaka EC. (2008). Analysis of five-year breast biopsies carried out in the university of Benin teaching hospital Benin city. *Niger Postgrad Med J*, **15**, 160-3.
- Pradhan M, Dhakal HP. (2008). Study of breast lumps of 2,246 cases by fine needle aspiration. *J Nepal Med Assoc*, **47**, 205-9.
- Pradhananga KK, Baral M, Shrestha BM (2009). Multi-institution hospital-based cancer incidence data for Nepal: An initial report. *Asian Pac J Cancer Prev*, **10**, 259-62.
- Reid-Nicholson MD, Tong G, Cangiarella JF, et al (2006). Cytomorphologic features of papillary lesions of the male breast: A study of 11 cases. *Cancer*, **108**, 222-30.
- Sidharth, Thapa B, Singh Y, et al (2008). Mammographic

Rajendra Kumar

diagnosis of breast carcinoma: An institutional experience. *J Nepal Med Assoc*, **47**, 62-5.

Silverberg SG, Masood S (1983). Principle and practice of surgical pathology and cytopathology, 3rd ed., Churchill livingstone.

Skandarajah AR, Field L, Yuen Larn Mou A, et al (2008). Benign papilloma on core biopsy requires surgical excision. *Ann Surg Oncol*, **15**, 2272-7.

Tea MK, Asseryanis E, Kroiss R, et al (2010). Surgical breast lesions in adolescent females. *Pediatr Surg Int*, **25**, 73-5.

Tiwari M (2007). Role of fine needle aspiration cytology in diagnosis of breast lumps. *Kathmandu Univ Med J*, **5**, 215-7.